

ACUTE DIGITALIS TOXICITY PRESENTING AS BRADYCARDIA IN PATIENT WITH ATRIAL FIBRILLATION WITH HEART FAILURERaymondPranata¹, Emir Yonas², Veresa Chintya³¹General Practitioner, Tabanan General Hospital, Tabanan, Bali, Indonesia ²Faculty of Medicine, YARSI University, Jakarta, DKI Jakarta, Indonesia ³General Practitioner, Sanjiwani General Hospital, Gianyar, Bali, Indonesia**ABSTRACT**

INTRODUCTION: Digitalis is used for atrial fibrillation to reduce the ventricular rate and has narrow therapeutic window. Mortality associated with unrecognized digitalis intoxication is high and often unacknowledged.

CASE ILLUSTRATION: A 86 years old male presented with fatigue since 1 day before admission. PMH of AF, HHD, CHF and CKD. PE: BP 90/60, HR: 48 bpm, RR: 20x/minute. ECG: AF SVR 40-50x/minute 'reverse tick sign' ST depression, LAD. Lab: Hyperkalemia and eGFR 22.92 mL/min. Previous echocardiography: Grade III diastolic dysfunction + LVH. IV hydration was given using normal saline 200 mL initially, insulin and glucose were administered to reduce potassium level.

DISCUSSION: Digitalis cause an increase in vagal activity and prolong conduction in the AV node, excessive effect in this patient cause reduced ventricular rate. ST-segment depression resembling a 'reverse tick' signified digitalis effect not necessarily toxicity. Digitalis toxicity can emerge even when the serum digitalis concentration is within the therapeutic range. The narrow therapeutic index of and pharmacokinetic changes associated with aging increases the risk of toxicity. The elimination of digitalis is mainly by renal clearance and is prolonged in CKD. This patient was an elderly and has eGFR of 22.92 mL/min, hence in high risk of digoxin toxicity. Ideally, digitalis Fab fragments is indicated for a K⁺ level greater than 5 mmol/L. **CONCLUSION:** Atrial fibrillation is the most common sustained arrhythmia and digoxin is widely used as rate control especially in those with heart failure. Digitalis toxicity is important to recognize and receive prompt treatment should toxicity arises.

Keywords: digitalis, digoxin, toxicity, atrial fibrillation

ABSTRAK

PENDAHULUAN: Digitalis digunakan pada fibrilasi atrium untuk menurunkan laju ventrikel namun memiliki jendela indeks terapeutik yang sempit. Mortalitas yang berhubungan dengan intoksikasi digitalis tinggi dan sering terlewatkan.

ILUSTRASI KASUS: Seorang laki-laki berumur 86 tahun datang dengan lemas sejak 1 hari SMRS. Riwayat AF, penyakit jantung hipertensif, gagal jantung kongestif dan gagal ginjal kronis. PF: TD 90/60, N: 48x/menit, Pernafasan: 20x/menit. EKG: FA SVR 40-50x/menit dengan ST depresi 'reverse tick sign'. Lab: hiperkalemia dan eGFR 22.92 mL/menit. Ekokardiografi sebelumnya: Disfungsi diastolik grade III dengan LVH. Hidrasi intravena diberikan dengan NS 200 ml, insulin dan glukosa diberikan untuk menurunkan kadar potassium.

DISCUSSION: Digitalis menyebabkan peningkatan aktifitas vagal dan memperlambat konduktifitas pada nodus AV, efek yang berlebihan pada pasien ini menurunkan laju ventrikel. Depresi segmen ST yang menyerupai 'reverse tick' sign menandakan efek digitalis belum tentu toksisitas. Toksisitas digitalis dapat muncul meskipun konsentrasi digoxin serum dalam batas terapeutik. Indeks terapeutik yang sempit dan perubahan farmakokinetik yang berhubungan dengan penuaan meningkatkan resiko toksisitas. Eliminasi digitalis terutama adalah melalui ginjal dan dapat terganggu pada pasien gagal ginjal kronik. Pasien ini tua dan memiliki eGFR 22.92 mL/menit sehingga memiliki resiko toksisitas yang tinggi. Secara ideal Fab fragmen digoxin diindikasikan untuk hiperkalemia diatas 5 mmol/L.

KESIMPULAN: Fibrilasi atrium adalah salah satu aritmia yang paling sering dan digitalis sering kali digunakan sebagai kendali laju ventrikel pada pasien FA dengan gagal jantung. Toksisitas digitalis penting untuk diketahui dan memerlukan penatalaksanaan segera.

Kata kunci: digitalis, digoxin, toksisitas, fibrilasi atrium

Correspondence :RaymondPranata¹, Emir Yonas², Veresa Chintya³

¹General Practitioner, Tabanan General Hospital, Tabanan, Bali, Indonesia ²Faculty of Medicine, YARSI University, Jakarta, DKI Jakarta, Indonesia ³General Practitioner, Sanjiwani General Hospital, Gianyar, Bali, Indonesia

Ph:0811 813 086

How to cite this article :

ACUTE DIGITALIS TOXICITY PRESENTING AS BRADYCARDIA IN PATIENT WITH ATRIAL FIBRILLATION WITH HEART FAILURE

INTRODUCTION

Digitalis/Digoxin inhibits $\text{Na}^+\text{-K}^+\text{-ATPase}$ which disrupt the function of Na^+ pump causing accumulation of intracellular Na^+ alters the $\text{Na}^+\text{-Ca}_2$ exchange leading to intracellular accumulation of calcium ions and positive inotropic effect but also the risk of tachyarrhythmias.¹Digitalis used for atrial fibrillation to reduce the ventricular rate by its AV nodal blocking agent effect due to alteration in depolarization. Digitalis has narrow therapeutic window and mortality associated with unrecognized digitalis intoxication is high and often unacknowledged. This is one of major limiting factor in using digoxin. The aim of this article is to discuss about digitalis toxicity which resulted in bradycardia.

CASE ILLUSTRATION

A 86 years old male presented with fatigue since 1 day before admission. He has a history of atrial fibrillation, hypertensive heart disease, chronic heart failure, and chronic kidney disease. Physical examination reveals blood pressure of 90/60 mmHg, heart rate of 48 bpm, respiratory rate of 20x/minute. Electrocardiography showed atrial fibrillation with slow ventricular response of 40-50x/minute with 'reverse tick sign' ST depression suggestive of digitalis effect and left axis deviation (Fig 1). Laboratory results showed hyperkalemia 5,5 mmol/L and eGFR 22,92 mL/min. Previous echocardiography showed grade III diastolic dysfunction and left ventricular hypertrophy. Intravenous hydration was given using normal saline 200 mL initially, insulin and glucose were administered to reduce potassium level.

DISCUSSION

Derived from *Digitalis lanata*, a species of the foxglove plant, digoxin increases intracellular calcium in myocardial cells through inhibiting the Na-K-ATPase . Inhibition of this pump causes hyperkalemia that is commonly seen in toxicity and in this patient.² Based on analyses of Digitalis Investigation Group study, the recommended target level of serum digoxin concentration is <1.0 ng/mL. The study found that less mortality and rehospitalization rate in heart failure patients when digoxin at a serum concentration was 0,5-0,9 ng/mL. The recommended approach for digoxin administration and monitoring in heart failure patient is to achieve a serum digoxin concentration of 0,7-1,1 ng/mL. Digoxin 0,25 mg orally can be started and serum concentration should be checked after 5 days (should be checked ≥ 6 hours after last oral dose) in patients. Oral digoxin 0,125 mg daily could be started in those with eGFR of 60-89 mL/min and 0,125 mg every other day in those with eGFR 30- 59 mL/min, serum digoxin should be checked at 4 days in this patient. While a creatinine clearance of <30 should warrant extreme caution of digoxin use.³ Digoxin also causes an increase in vagal activity and prolong conduction in the atrioventricular node, excessive effect in this patient cause reduced ventricular rate. At therapeutic levels, it decreases automaticity and increases the cellular membrane potential. In toxic concentrations, however, arrhythmias may originate from increased cell excitability secondary to a decreased resting cellular membrane potential. After depolarizations and after contractions may result in increased automaticity which is

due to spontaneous cycles of Ca^{2+} release and reuptake. Almost all arrhythmia may occur because of digitalis toxicity except for atrial tachycardia with rapid ventricular response due to slow conduction in AV node in digitalis toxicity.^{2,3} The classical arrhythmia associated with digitalis toxicity is tachycardia with sinus or AV nodal suppression. ST-segment depression resembling a 'reverse tick' signifies a digitalis effect which is not necessarily a toxicity. Digoxin toxicity can emerge during long-term therapy as well as after an overdose. It can occur even when the serum digoxin concentration is within the therapeutic range. The narrow therapeutic index of digoxin and pharmacokinetic changes associated with aging increases the risk of toxicity. The elimination of digoxin is mainly by renal clearance and its half-life (36 hours in those with normal renal function) might be prolonged in patients with renal impairment. In patients with ESRD the half-life may be around 4 to 6 days.^{2,3} Dialysis is ineffective in patients with digitalis toxicity due to extensive distribution into fat.³ This patient was an elderly and has eGFR of 22,92 mL/min (CKD stage IV), hence in high risk of digoxin toxicity and as discussed above, requires extreme caution. Intravenous hydration given cautiously was the supportive therapy for low blood pressure. Insulin and glucose was used to reduce hyperkalemia. Ideally, digoxin Fab fragments is indicated in those with potassium level greater than 5 mmol, cardiac arrest and life-threatening arrhythmia.^{4,5,6} This patient has high potassium level and may be given the digoxin Fab fragments, however, it is also costly and was unavailable. Studies showed varying mortality in digoxin toxicity, ranging from around 20 to 30%.⁷⁻¹¹

CONCLUSION

Atrial fibrillation is the most common sustained arrhythmia and digoxin is widely used as rate control especially in those with heart failure. Digoxin might be hazardous. However, since limited options are available, it is important to recognize and promptly treat the toxicity.

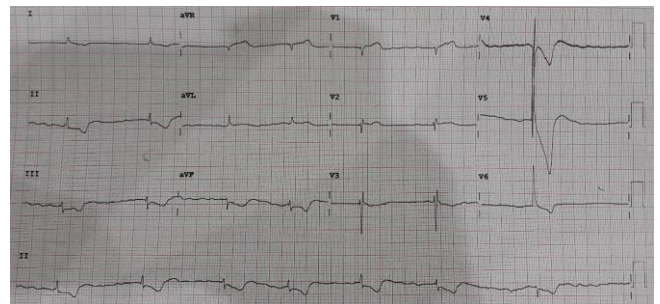


Figure 1. Patient's ECG showing AF SVR and reverse-tick sign

REFERENCES

1. Zipes DP, Jalife J, eds. Cardiac electrophysiology: From cell to bedside. 7th edition. Philadelphia: WB Saunders 2017.
2. Pincus M. Management of digoxin toxicity. *AustPrescr* 2016;39(1):18–20. doi: 10.18773/austprescr.2016.006
3. Yang E.H., Shah S., Criley J.M. Digitalis toxicity: A fading but crucial complication to recognize. *Am. J. Med.* 2012;125(4):337–343. doi: 10.1016/j.amjmed.2011.09.019
4. Nelson L, Goldfrank LR. Goldfrank's Toxicologic emergencies. 9th ed. New York: McGraw-Hill Medical; 2011.
5. Murray L, Daley F, Little M, Cadogan M. Toxicology handbook. 2nd ed.

- Sydney: Elsevier; 2011.
6. Hickey AR, Wenger TL, Carpenter VP, et al. Digoxin Immune Fab therapy in the management of digitalis intoxication: safety and efficacy results of an observational surveillance study. *J Am Coll Cardiol.* 1991;17:590–598.
 7. Bismuth C, Motte G, Conso F, et al. Acute digitoxin intoxication treated by intracardiac pacemaker: experience in sixty-eight patients. *Clin Toxicol.* 1977;10:443–456.
 8. Tabolet P, Baud FJ, Bismuth C. Clinical features and management of digitalis poisoning--rationale for immunotherapy. *J Toxicol Clin.* 1993;31:247–260.
 9. Antman EM, Wenger TL, Butler VP, Jr, Haber E, Smith TW. Treatment of 150 cases of life-threatening digitalis intoxication with digoxin-specific Fab antibody fragments. Final report of a multicenter study. *Circulation.* 1990;81:1744–1752.
 10. Lapostolle F, Borron SW, Verdier C, Arnaud F, Couvreur J, Megarbane B, et al. Assessment of digoxin antibody use in patients with elevated serum digoxin following chronic or acute exposure. *Intensive Care Med.* 2008;34:1448–1453.